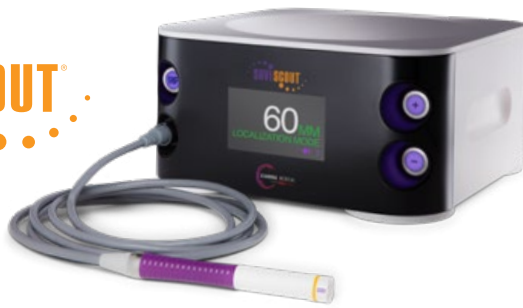



Axillary Lymph Node Marked with SCOUT® Prior to Neoadjuvant Chemotherapy

Erica Giblin, MD

Breast Surgical Oncologist
Medical Director, Breast Care Services
St. Vincent Medical Group, Indianapolis, IN

Patient: 55-year-old female

Diagnosis: Invasive Ductal Carcinoma Stage II (T2 N1 M0)

Rx: SCOUT localized lumpectomy, SCOUT localized axillary node sentinel node biopsy

Challenge: Intraoperative identification of biopsy proven malignant node following neoadjuvant chemotherapy

Patient History

A 55-year-old female presented with a palpable mass in the left upper outer quadrant, identified on self-examination. She had no family history of breast or ovarian cancer. Diagnostic mammogram was notable for a 2.4 cm spiculated mass corresponding to the palpable mass. Ultrasound was notable for a 2 cm hypoechoic lesion with irregular margins in the left upper outer quadrant at 2:00 position, 10 CFN. US core biopsy revealed grade II invasive ductal cancer, ER positive, PR positive, HER2 positive. Ultrasound of the axilla revealed a 1.64 cm left axillary node with an asymmetrically thickened cortex. (Figure 1) Core biopsy of the node reveal metastatic disease consistent with breast

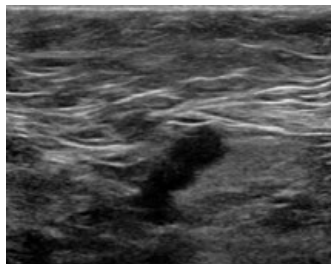


Figure 1

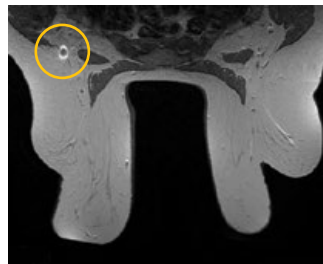


Figure 2

primary. Breast MRI demonstrated biopsy-proven malignancy as an enhancing mass measuring 1.8 x 1.7 x 1.8 cm with no evidence of multifocal or multicentric disease, and an enlarged left axillary lymph node with cortical thickening, marked with the biopsy clip. (Figure 2)

Neoadjuvant Therapy

Neoadjuvant chemotherapy was planned (Docetaxel, Carboplatin, Trastuzumab and Pertuzumab). Prior to initiating, a SCOUT reflector was placed into the metastatic axillary node. Upon clinical restaging, her post-chemotherapy imaging revealed that the mass had decreased in size to 1.2 cm in largest dimension concentrically. US evaluation of the left axillary node revealed no residual cortical thickening.

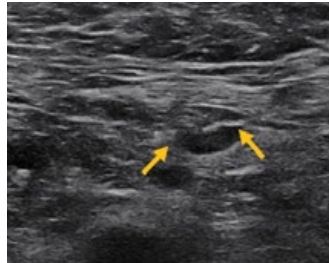


Figure 3

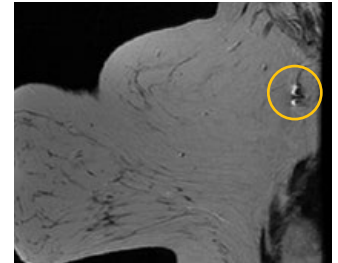


Figure 4 (LT SAG T2)

MRI and ultrasound revealed the SCOUT reflector and biopsy clip in the left axilla at the site of the prior metastatic node. No enlarged left axillary nodes were seen. (Figures 3 & 4)

Surgery

Following a five-month course of neoadjuvant chemotherapy, a SCOUT localized left breast lumpectomy with concomitant oncoplastic reduction, sentinel node biopsy and SCOUT localized axillary node excision were planned. Specimen imaging confirmed the presence of a SCOUT reflector and core biopsy clip in both the lumpectomy and the axillary node specimens. (Figure 5) Immediate frozen section of the SCOUT localized node was positive for metastatic disease. The patient subsequently underwent immediate axillary dissection.

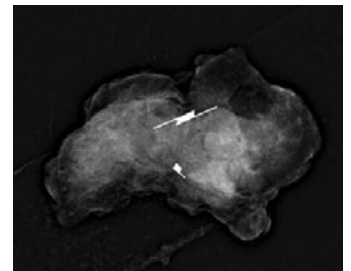
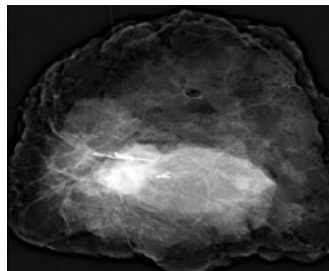


Figure 5

Pathology

Final surgical pathology revealed the left lumpectomy specimen to contain 1.6 cm of grade II invasive ductal cancer and one of 10 axillary nodes with metastatic carcinoma.

Conclusion

SCOUT localization of a known biopsy proven metastatic node prior to initiation of neoadjuvant chemotherapy ensures the node can be localized and removed in the post-neoadjuvant surgical setting. It is known that core biopsy proven axillary nodes with excellent response to neoadjuvant chemotherapy can be difficult to localize after treatment due to the node regaining 'normal' characteristics, and challenges with viewing the core biopsy clips months after placement. Placement of a SCOUT reflector prior to initiation of neoadjuvant chemotherapy mitigates these issues and allows for confidence in removing the node of concern intraoperatively.



ciannamedical.com/savi-scout
merit.com

The foregoing case and other information are for the practitioner's convenience and for general information purposes only. This information does not constitute medical or legal advice, nor is it meant to endorse or guarantee the suitability of any of the referenced products or methods for any specific patient or procedure. Before using any product, refer to the Instructions for Use (IFU) for indications, contraindications, warnings, precautions, and directions for use.