

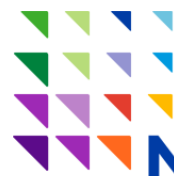SCOUT Report

News and Views on Surgical Guidance
and Breast Tumor Localization



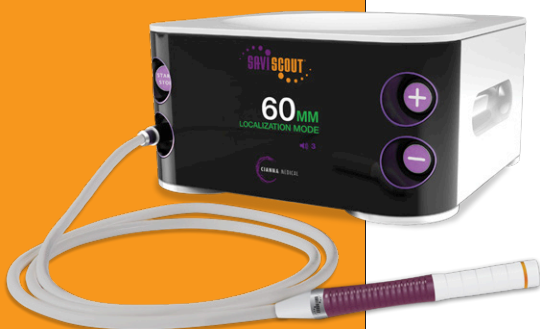A 21st Century Approach to TLC: Leveraging Technology to Improve Care

Don't miss the recent article highlighting one major healthcare system's transition to wire-free localization. Their experience is offered as a roadmap for implementing medical innovation across a large healthcare network to



the benefit of patients, physicians, clinical operations and the organization's bottom line:

**Northwell
Health®**



- Increased efficiencies for both radiology and surgery departments
- Reduced downtime for radiology and surgery staff, which eliminates unnecessary costs
- Patients can schedule procedures at the time and location of their choosing
- Patients who had previously undergone wire-based localization report that the wire-free approach is more comfortable and convenient

[***Click here to read the full article***](#)

Case Review: Specimen Assessment with SCOUT® Distance Measurement

Rie Aihara, MD

Medical Director, Surgical Breast Oncologist
Regional Breast Care, Ft. Myers, FL

Patient: 66-year-old female

Preoperative Diagnosis: Ductal Carcinoma In Situ

Postoperative Diagnosis: Invasive ductal carcinoma and DCIS, T1, N0, M0 Stage 1

Procedure: Left breast SCOUT localized partial mastectomy for DCIS

Patient History

The patient is a 66-year-old caucasian female with a family history of breast cancer. Annual screening mammogram revealed a new cluster of microcalcifications in the 3 o'clock position of the left breast, and a stereotactic biopsy was performed. Post-biopsy imaging confirmed the presence of a well-positioned clip and pathology revealed a low-grade ductal carcinoma in situ with an ER/PR positive status. Preoperative MRI showed closely approximated 1.3 cm and 0.6 cm areas of abnormal mass enhancement related to the biopsy clip within the upper outer quadrant of the left breast corresponding to her biopsy proven DCIS with no other areas of suspicious enhancement in either breast. She elected to undergo breast conservation therapy and a SAVI SCOUT® localized partial mastectomy was performed.

Procedure

The patient underwent a mammography-guided SCOUT reflector placement one week prior to surgery. On the day of surgery, using the post reflector placement mammogram and the SCOUT system as guidance, the reflector was identified at the 3 o'clock position in the lateral aspect of the left breast. A transverse incision was made over the strongest obtained signal. Upon entering the subcutaneous tissue, the distance to the reflector was measured to be 5-6 mm using the

Margin	Margin-to-reflector distance
Anterior	1 mm*
Inferior	3 mm*
Posterior	11 mm
Superior	7 mm
Lateral	13 mm
Medial	9 mm

*Additional margins taken

SCOUT console. Using the guidance of the handpiece from all sides of the target, a partial mastectomy was performed. The excised specimen, once labeled with orientation sutures, was evaluated using the SCOUT system by recording the distance from each margin to the reflector (see table).

The approximate specimen size was 3 x 3 x 2 cm. Radiographic evaluation confirmed the presence of the biopsy clip and reflector within the specimen. Based on imaging and the distance analysis, the reflector appeared closest to the inferior and anterior margins (see Figure 1). Additional margins were thus taken for safety.

Pathology

In addition to the known DCIS, two small foci of grade 2 invasive ductal carcinoma measuring 8 mm and 5 mm were found on final pathology. Both of these tumors were noted to be ER/PR positive, and HER-2 negative with genomic low risk of recurrence. The closest margins were anterior and inferior at 4 mm.

Because of her invasive component, the patient did return to the operating room for sentinel lymph node assessment with analysis of 2 lymph nodes that were negative. She proceeded with radiation therapy and endocrine therapy.

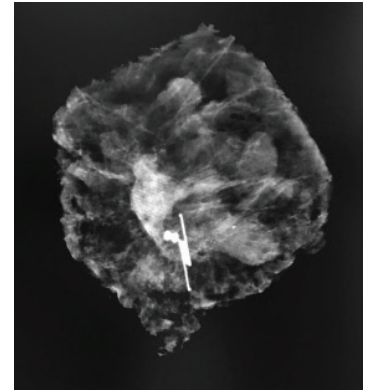


Figure 1: Showing specimen radiograph, SCOUT reflector and biopsy clip.

Conclusion

The inability to visualize the marking clip, localizing devices or the actual tumor intraoperatively renders it difficult to estimate the amount of tissue present between the target and the margins. The SCOUT distance system in this case allowed for an objective measurement of the reflector to the margin. Final pathology confirmed the distance to be accurate. Surgeons rely on specimen imaging to guide the decision to take additional tissue based on visual proximity, however, the SCOUT system provided an additional objective measurement to help guide decision making intraoperatively to minimize the need for return to the operating room.

[Click here to download a PDF of the full case review by Dr. Aihara](#)



Cianna Medical, Inc., 6 Journey, Suite 125, Aliso Viejo, California 92656
866.920.9444 • 949.360.0059 • Fax 949.297.4527
www.ciannamedical.com

©2018 Cianna Medical, Inc. All rights reserved. These products covered by U.S. Patents 8,892,185, 9,386,942, 9,713,437. Other patents pending. BEST Forum, SAVI, SCOUT, SAVI SCOUT, SCOUT Check and Cianna Medical are registered trademarks of Cianna Medical, Inc. TRUELOC is a pending trademark application in U.S. Patent and Trademark Office in the name of Cianna Medical, Inc.