

## Pilot Study of a New Nonradioactive Surgical Guidance Technology for Locating Nonpalpable Breast Lesions

Charles E. Cox, MD<sup>1</sup>, Norbert Garcia-Henriquez, MD<sup>1</sup>, M. Jordan Glancy, BS<sup>1</sup>, Pat Whitworth, MD<sup>2</sup>, John M. Cox, MD<sup>3</sup>, Melissa Themar-Geck, MD<sup>4</sup>, Ronald Prati, MD<sup>4</sup>, Michelle Jung, BS<sup>1</sup>, Scott Russell, MS<sup>1</sup>, Kristie Appleton<sup>2</sup>, Jeff King, BS<sup>1</sup>, and Steven C. Shivers, PhD<sup>1</sup>

<sup>1</sup>University of South Florida (USF) Breast Health Program, USF Morsani College of Medicine, Tampa, FL; <sup>2</sup>Nashville Breast Center, Nashville, TN; <sup>3</sup>Tampa Bay Breast Care Specialists, Tampa, FL; <sup>4</sup>The Breast Care Center at Florida Hospital Tampa, Tampa, FL

### ABSTRACT

**Background.** The current technique for locating nonpalpable breast lesions is wire localization (WL). Radioactive seed localization and intraoperative ultrasound were developed to improve difficulties with WL. The SAVI SCOUT surgical guidance system was developed to improve these methods. The SCOUT system is a non-radioactive, FDA-cleared medical device that uses electromagnetic wave technology to provide real-time guidance during excisional breast procedures.

**Methods.** Consenting patients underwent localization and excision using an implantable electromagnetic wave reflective device (reflector) and a detector handpiece with a console. Using image guidance, the reflector was placed up to 7 days before the surgical procedure. The primary end points of the study were successful reflector placement, localization, and retrieval. The secondary end points were percentage of clear margins, reexcision rates, days of placement before excision, and physician comparison with WL.

**Results.** This study analyzed 50 patients. The reflectors were placed under mammographic guidance ( $n = 18$ , 36 %) or ultrasound guidance ( $n = 32$ , 64 %). Of the 50 patients, 10 (20 %) underwent excisional biopsy and 40 (80 %) had a lumpectomy. The lesion and reflector were successfully removed in all 50 patients, and no adverse events occurred. Of the 41 patients who had in situ and/or invasive carcinoma identified, 38 (93 %) had clear margins and 3 (7 %) were recommended for reexcision.

**Conclusions.** These data suggest that the SCOUT system is safe and effective for guiding the excision of nonpalpable breast lesions and a viable alternative to standard localization options. A larger prospective, multi-institution trial of SCOUT currently is underway to validate these findings.

The identification of early, nonpalpable breast cancers continues to rise with increasing use of screening mammography and improved imaging technologies. The standard technique for locating nonpalpable lesions is wire localization (WL). Developed more than 20 years ago, WL has been shown to have several procedural and workflow-related pitfalls.<sup>1</sup> The procedural challenges include discrepancy between the wire entry site and the ideal surgical approach, variation in wire tip placement relative to the lesion, wire migration, and transection. These challenges often lead to inaccuracy in removal of target tissue, with the potential for excessive tissue removal, suboptimal cosmetic results, and inadequate margins. Positive margins have been reported in 12–60 % of WL cases.<sup>2–6</sup>

From a workflow perspective, the wire must be placed the day of surgery to reduce the risk of wire migration because the wire extends out of the patient's breast. This limitation directly couples radiology and operating room schedules, resulting in costly delays, radiology rescheduling (eliminating the ability to schedule a wire-guided surgery first thing in the morning), and a suboptimal patient experience.<sup>2,7</sup>

Radio-guided surgical techniques with implantable seeds [<sup>125</sup>I radioactive seed localization (RSL)], injectable radio-colloid, and intraoperative ultrasound (IOUS) have been developed and recently tested clinically. These techniques

offer simplicity, lower margin positivity, fewer reexcisions, better coordination of patient care, and increased patient satisfaction. Although these techniques appear superior to WL, they too have challenges that have had an adverse impact on their adoption.

This report introduces the SAVI SCOUT® surgical guidance system (Cianna Medical, Inc., Aliso Viejo, CA). This system was designed to advance the progress made with radio-guided and ultrasound localization techniques. This novel Food and Drug Administration (FDA)-cleared medical device uses nonradioactive electromagnetic wave and infrared light technology to provide real-time guidance during excisional breast procedures. For the first time, SCOUT combines electromagnetic wave technology with infrared light for use in surgical guidance. This pilot study aimed to evaluate the performance and to estimate the safety and efficacy of the SCOUT system in locating and directing the removal of nonpalpable breast lesions during lumpectomy and excisional biopsy procedures.

## METHODS

This study was an institutional review board (IRB)-approved, multi-institutional pilot investigation. All the consenting research participants were women between the age of 18 and 90 years with a newly diagnosed nonpalpable breast lesion scheduled for either excisional biopsy or lumpectomy between July, 2014 and January, 2015 (Table 1). The lesion depth had to be 3 cm or less, and patients with previous ipsilateral breast cancer, multicentric disease, or neoadjuvant chemotherapy were excluded from the study.

The FDA-cleared SCOUT system includes an implantable, infrared-activated, electromagnetic wave-reflective device (reflector), a detector handpiece, and a console (Fig. 1). The reflector is percutaneously inserted into the target tissue through a delivery needle under image

guidance before surgery. The handpiece emits electromagnetic waves and noninjurious infrared light into the breast tissue and in turn receives an electromagnetic wave signal reflected back from the reflector. Audible feedback from the console increases in cadence with increasing handpiece-to-reflector proximity. The system provides real-time direction and proximity guidance to target the implanted device and guide surgical removal of the lesion.

The unique design of the reflector makes it detectable by the SCOUT system. The reflector consists of antennas together with infrared light receptors and a transistor switch. When receiving an infrared light pulse emitted by the handpiece, the infrared light receptors close the transistor switch connected to the antennas reflecting a wave signal to the handpiece. This sophisticated combination of electromagnetic wave and infrared light technology allows the handpiece and console to exclusively detect the reflector.

The reflector can be placed up to 7 days before surgery using either sonographic or mammographic guidance. The delivery system, preloaded with the reflector, consisted of a 16-gauge, 13-cm needle. In this study, after injection of a local anesthetic, the reflector was percutaneously introduced through the delivery system needle. Once it reached the desired location, the physician deployed the reflector and confirmed positioning using ultrasound or mammography (Fig. 2). All patients underwent postplacement verification with the handpiece and console to confirm reflector detectability.

At the time of surgery, the surgeon placed a new sterile handpiece in contact with the skin to detect the location of the reflector and to plan the appropriate skin incision and approach. During the surgical procedure, the dissection was directed by the handpiece and continuous feedback from the console. Repeated handpiece placement inside the incision provided direction and proximity information to the reflector and target tissue. Once removed, the specimen

**TABLE 1** Patient eligibility

---

### Inclusion criteria

---

Patient had a nonpalpable breast lesion that required excision  
 Lesion depth was  $\leq 3$  cm  
 Patient was scheduled for excision at a participating institution  
 Patient was female and between the ages of 18 and 90 years

---

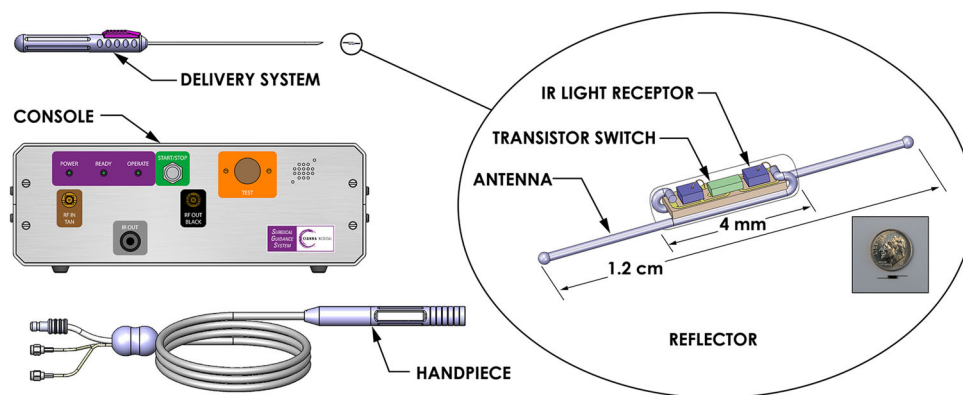
### Exclusion criteria

---

Patient had a previous ipsilateral breast cancer  
 Patient had multicentric breast cancer  
 Patient had stage 4 breast cancer  
 Patient had been treated with neoadjuvant chemotherapy  
 Patient was pregnant or lactating  
 Patient had known or suspected allergic reactions to materials similar to the components of the SCOUT reflector

---

**FIG. 1** The SAVI SCOUT system components



was interrogated with the handpiece to confirm reflector removal. Both lesion and reflector removal were verified with specimen radiography.

The primary end points of the study were successful reflector placement, lesion localization, and retrieval. The secondary end points were clear margin rate and physician comparison with WL.

## RESULTS

For this study, 60 patients consented to participate, but 7 patients were excluded before reflector placement due to scheduling problems ( $n = 4$ ) or subsequent determination of ineligibility ( $n = 3$ ) (Table 2). Each surgeon managed an initial training case, which was excluded from the data analysis. Of the 50 study cases analyzed, 23 (46 %) were managed by one of two surgeons at the University of South Florida, and 27 (54 %) were managed at the Nashville Breast Center by a single surgeon. The average patient age was 58.5 years.

All reflector placements were successful, with 18 (36 %) placed under mammographic guidance and 32 (64 %) placed under ultrasound guidance. Of the 50 patients, 31 (62 %) had reflectors placed the same day as surgery, and 19 had reflectors placed an average of 2.3 days (range 1–6 days) before surgery. Despite eligibility criteria calling for patients who had lesions with a depth of 3 cm or less, reflectors were placed up to 6 cm (average 2 cm; range 0.5–6 cm) from the skin due to localization constraints of the radiographic approach. On the average, the reflector was placed 2.8 mm (range 0–15 mm) from the target (lesion or biopsy marker).

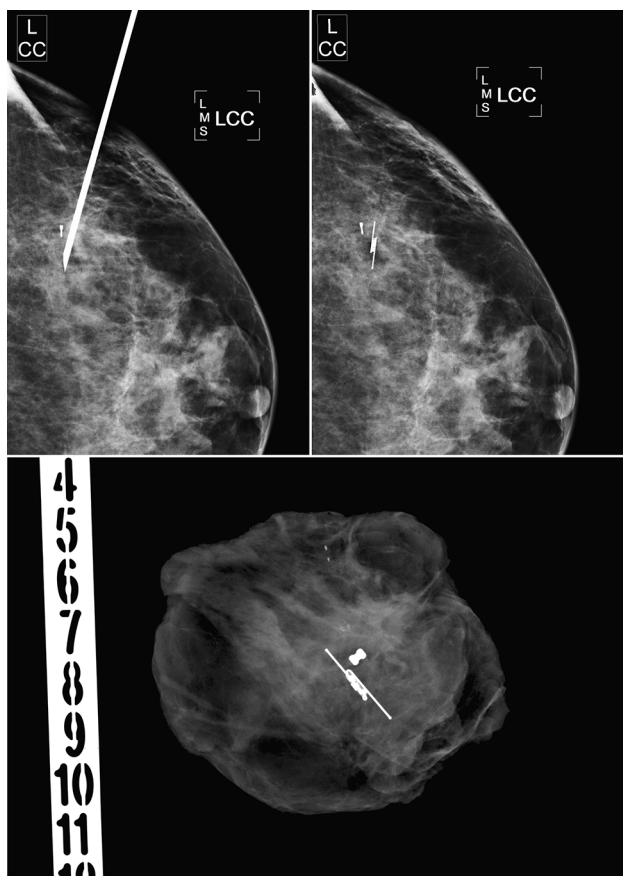
Two patients had reflectors that were not detected during the postplacement verification step. The reflectors in these cases were placed respectively 4.5 and 6 cm from the skin. Conversely, the remaining reflectors were successfully detected up to 4.5 cm from the skin. In both nondetection cases, instead of defaulting to WL, the investigator elected to proceed to surgery with SCOUT for guidance. Both

reflectors were detected at the initial skin incision, and the handpiece guided a successful dissection and removal. No other type of guidance was used, and neither patient required reexcision.

Of the 50 patients, 10 (20 %) underwent excisional biopsy and 40 (80 %) underwent lumpectomy procedures. At the time of surgery, the reflector was successfully detected before the incision in 44 (88 %) of the 50 patients up to 4.5 cm from the skin (Table 2). In the six cases in which the reflector was not detected from the skin, the reflector location was approximated from the postplacement mammography images for incision planning. In five of these six cases, the reflector was detected immediately after the initial skin incision. The remaining case resulted from a malfunction of the reflector, a problem subsequently identified and corrected by the manufacturer.

In two cases, the reflector was not consistently detected with the handpiece during the surgical dissection after the skin incision. As noted previously, in the one case, the detection inconsistency resulted from a malfunction whereby the reflector functioned intermittently yet sufficiently to allow for successful guidance and removal. In the other case, detection was lost at contact of the reflector by electrocautery, signifying that the reflector and target tissue had been reached. Based on this occurrence, the manufacturer incorporated an additional component into the reflector to maximize detectability should it be contacted by a cautery device. For the cases in which the detector was not consistently detected before or after the incision, SCOUT provided the sole method of surgical guidance, with successful removal of the target lesion and reflector with no margin reexcisions required.

The reflector was successfully removed from all 50 patients, and reflectors were confirmed within the target lesion by specimen radiography. Reflector migration was not directly measured but was not observed as determined by comparison of postplacement images and specimen radiographs. No adverse events occurred. Overall, using a scale of 1–10 (5 = the same as WL, <5 = worse than WL,



**FIG. 2** Reflector placement with mammographic guidance adjacent to an existing biopsy marker (*top*). Specimen radiograph (*bottom*)

>5 = better than WL), the surgeons rated the ease of localization and removal at respectively 9.2 and 9.4, and the radiologists rated ease of placement and patient comfort at 4.1 and 4.5.

The final pathology identified no invasive or in situ carcinoma in 9 of the 10 excisional biopsy patients (Table 3). Invasive carcinoma, ductal carcinoma in situ (DCIS), or both were identified in 41 patients: DCIS alone in 10 patients, invasive carcinoma alone in 15 patients, and a combination of the two in 16 patients. The average tumor size in all the patients with cancer was 1.3 cm (range 0.1–2.7 cm). Of these patients, 38 (93 %) had clear margins, whereas 9 (22 %) had close margins to within 1 mm. Only 3 of the 41 patients (7 %) with cancer were recommended for margin reexcision.

## DISCUSSION

The standard technique for locating nonpalpable breast lesions is WL, for which disadvantages have been well documented. The wire entry point often is chosen, based on ease of access, as opposed to the ideal surgical approach. From postplacement images, the surgeon must estimate the

pathway to the lesion, leading to inaccuracy in locating the target lesion.<sup>8</sup> Wire migration can cause excessive tissue removal, and wire transection can leave fragments within the breast. Findings also have shown WL to be inaccurate in achieving negative margins, with reexcision rates reported to be as high as 60%.<sup>2,3,5,6,9</sup> Because the wire must be placed on the day of the operation, WL directly couples surgery and radiology schedules, which can be an inconvenience for the patient, radiologist, surgeon, and operating room staff.

The RSL approach, initially described by our group in 2001, has proved to be an excellent localization technique superior to WL.<sup>2,10</sup> Because RSL allows real-time reorientation of the dissection toward the target lesion, it can result in an absolute decrease in positive margin and reexcision rates.<sup>2,3,10,11</sup> Hughes et al.<sup>9</sup> reported a reexcision rate of 8 % with RSL versus 25 % with WL. Furthermore, the ability to place the seed entirely within breast tissue results in an extremely low likelihood of migration.<sup>12</sup> Despite these advantages, regulatory issues associated with the handling radioactive seeds have had a substantial impact on adoption.

The IOUS technique, another approach for localizing nonpalpable lesions, has been shown to yield lower reexcision rates than WL.<sup>13–15</sup> With IOUS, the lesion, hematoma, or biopsy marker must be sonographically visible. Because IOUS requires ultrasound equipment, training, and competence in interpreting ultrasound images, it may not be available to all surgeons. Also, IOUS requires removal of retractors, dimming of the operating room lights, scanning with the ultrasound probe, and replacement of the retractors as the lesion is removed. Ultrasound-visible hydrogel-based markers offer the advantage of placement at the time of biopsy, but these markers may lack visibility, may migrate, or may be dislodged at removal.<sup>16,17</sup>

The SCOUT surgical guidance system was developed to overcome the aforementioned disadvantages of standard techniques for locating nonpalpable breast lesions. The reflector can be placed from any direction without having an impact on the surgical approach, allowing for optimal incision placement. The system provides real-time continuous feedback during the dissection, allowing course correction to ensure accurate removal of the reflector and lesion while minimizing tissue removal.

In this study, the handpiece guided the entire dissection from the skin surface in most cases. However, even when the reflector was not detected from the skin surface, the approximate reflector location was known from the post-placement images, which allowed for successful surgical guidance of the dissection, with removal of all reflectors and no margin reexcisions. Although the results do not indicate a clear depth at which the handpiece will detect the reflector, they do suggest a maximum depth of 4–5 cm for

**TABLE 2** Patient and study characteristics

	University of South Florida <i>n</i> (%)	Nashville Breast Center <i>n</i> (%)	All cases <i>n</i> (%)
<b>Patient enrollment</b>			
Consenting patients	32	28	60
Off-study cases	7	0	7
Training cases (data not included)	2	1	3
Study cases (data analyzed)	23	27	50
Mean patient age: years (range)	58.7 (37–80)	58.3 (41–77)	58.5 (37–80)
<b>Reflector placements</b>			
Mammography guidance	18 (78)	0 (0)	18 (36)
Ultrasound guidance	5 (22)	27 (100)	32 (64)
Mean reflector distance from skin: cm (range)	2.8 (0.5–6.0)	1.3 (0.7–2.2)	2.0 (0.5–6.0)
Mean reflector distance from target: mm (range)	4.7 (0.0–15.0)	1.2 (0.0–12.0)	2.8 (0.0–15.0)
Success of reflector placement	23 (100)	27 (100)	50 (100)
Radiologist evaluation: mean ease of placement <sup>a</sup>	4.1	10 <sup>b</sup>	–
Radiologist evaluation: mean patient comfort <sup>a</sup>	4.5	NA <sup>b</sup>	–
<b>Reflector localizations and excisions</b>			
Excisional biopsies	10 (43)	0 (0)	10 (20)
Lumpectomies	13 (57)	27 (100)	40 (80)
Cases with reflector placed on day of excision	4 (17)	27 (100)	31 (62)
Mean reflector placement before excision: days (range)	2.3 (1–6)	NA <sup>b</sup>	2.3 (1–6)
Reflector detected before incision	17 (74)	27 (100)	44 (88)
Reflector located after incision	22 (96)	26 (96)	48 (96)
Reflector successfully removed	23 (100)	27 (100)	50 (100)
Reflector detected on specimen radiograph	23 (100)	27 (100)	50 (100)
Reflector intact	23 (100)	27 (100)	50 (100)
Surgeon evaluation: mean ease of localization <sup>a</sup>	8.2	10.0	9.2
Surgeon evaluation: mean ease of removal <sup>a</sup>	8.7	10.0	9.4

NA not applicable

<sup>a</sup> Compared with wire localization (WL): scale of 1–10 in which 5 is the same as WL, <5 is worse than WL, and >5 is better than WL

<sup>b</sup> At this institution, all placements were performed by the surgeon on the day of surgery using ultrasound guidance while the patient was under anesthesia

initial cases while experience with the technology is gained. In the supine position, most breasts have a skin-to-chest wall distance within this range. A larger ongoing prospective, multi-institution study containing no depth restriction will further examine this subject.

The SCOUT system eliminates the regulatory hurdles presented by radioactive seeds, and compared with IOUS, eliminates the encumbrances of low lighting, minimal retraction, and loss of imaging due to tissue disruption from the incision. Although this study did not directly compare SCOUT with other techniques, the observed reexcision rate (7%) is comparable with those reported for RSL and IOUS.<sup>3,9,13,15,18–21</sup>

The ability to place the reflector up to 7 days before surgery eliminates scheduling conflicts between radiology and surgery. This uncoupling of radiology and surgery schedules, in contrast to RSL, can improve operating room

efficiencies by allowing excisional procedures to be performed early in the day. Likewise, radiology efficiencies and patient wait times are improved because the SCOUT system eliminates the need to reserve blocks in the schedule for same-day wire placements.<sup>7,22</sup> Uncoupling of the schedules also lowers the risk of vasovagal syncope associated with fasting required for same-day surgical localization.<sup>3,9,22,23</sup>

For cases in which the reflector was placed one or more days before the surgery (*n* = 19), the participating radiologists rated ease of placement and patient comfort slightly below that for traditional wires. These low scores are probably attributable to the reflector delivery system, which was designed specifically for ultrasound-guided placements. With a 13-cm needle and an overall length of 23 cm, the delivery system was too large for optimal use with mammography-guided placements. Based on recommendations by the participating radiologists, the reflector



**TABLE 3** Surgical pathology

	University of South Florida <i>n</i> (%)	Nashville Breast Center <i>n</i> (%)	All cases <i>n</i> (%)
Surgical pathology			
Benign	9 (39)	0 (0)	9 (18)
DCIS only	5 (22)	5 (19)	10 (20)
Invasive cancer only	4 (17)	11 (41)	15 (30)
DCIS + invasive cancer	5 (22)	11 (41)	16 (32)
Mean amount of tissue excised: cm <sup>3</sup> (range)	76.7 (5.8–828)	183.9 (38.8–301)	134.6 (5.8–828)
Cases with cancer	14	27	41
Mean tumor size: cm (range)	1.0 (0.1–2.4)	1.5 (0.1–2.7)	1.3 (0.1–2.7)
No tumor in specimen	1 (7)	3 (11)	4 (10)
All margins clear	12 (86)	26 (96)	38 (93)
Mean closest margin: mm (range)	2.7 (0.1–10)	4.3 (1.0–10)	3.8 (0.1–10)
Close margin within 2 mm	7 (50)	5 (19)	12 (29)
Close margin within 1 mm	6 (43)	3 (11)	9 (22)
Positive margin (tumor on ink)	2 (14)	1 (4)	3 (7)
Required reexcision	2 (14)	1 (4)	3 (7)

*DCIS* ductal carcinoma in situ

delivery system has been redesigned with a shorter, lighter handle and needle length options of 5, 7.5, and 10 cm.

The surgeons participating in this pilot study found SCOUT localization easier to perform than WL, similar to RSL compared with WL.<sup>24</sup> Surgical targeting with SCOUT, although similar in concept to that of radio-guided seed localization or sentinel lymph node identification, requires a different technique, and thus training is recommended. In detecting the reflector, a key technique to learn is the need to move the handpiece slowly to allow the system time to detect the reflector. This is particularly important from the skin surface because the system is more directional than a gamma probe. Based on this study, the manufacturer incorporated a display screen on the console to ensure optimal handpiece technique when the reflector is detected from the skin surface. Finally, frequent use of the handpiece is recommended to optimize the dissection and excision.

## CONCLUSIONS

Options for the surgical excision of nonpalpable breast lesions have been expanded with the SCOUT surgical guidance system, which uses nonradioactive electromagnetic wave technology to provide real-time guidance during lumpectomies and excisional biopsies. This study resulted in 100 % surgical success, with removal of both the target lesion and the reflector in all cases with a low rate of margin reexcision. Overall, the technology is highly intuitive, reliable, and easy to implement. The surgeons in

this study strongly favored SCOUT because it optimizes intraoperative surgical guidance, simplifies scheduling, and eliminates radioactivity-related hurdles. The SCOUT system is easy to learn and may enable improved radiology and operating room efficiencies, greater physician convenience, and enhanced patient satisfaction. This pilot study suggests that SCOUT is safe and effective for guiding the excision of nonpalpable breast lesions and a viable alternative to standard localization options. A larger prospective, single-arm, multi-institution, clinical evaluation of SCOUT is currently underway to validate these findings.

**ACKNOWLEDGMENT** This study was supported in part by an endowment from the Joy McCann Foundation. The clinical trial was funded by a Grant from Cianna Medical, Inc.

**DISCLOSURES** Charles E. Cox, MD, is a member of the speakers bureau for Cianna Medical, Inc. and has provided consultation to Cianna Medical to assist with the development of SAVI SCOUT. Dr. Cox was the principal investigator of the current study, which was funded by Cianna Medical for a total of \$5000 for data collection from up to 25 patients enrolled locally. The remaining authors have nothing to disclose.

## REFERENCES

- Al-Sobhi SS, Helvie MA, Pass HA, Chang AE. Extent of lumpectomy for breast cancer after diagnosis by stereotactic core versus wire localization biopsy. *Ann Surg Oncol*. 1999;6(4):330–35.
- Gray RJ, Salud C, Nguyen K, et al. Randomized prospective evaluation of a novel technique for biopsy or lumpectomy of

- nonpalpable breast lesions: radioactive seed versus wire localization. *Ann Surg Oncol.* 2001;8(9):711–5.
3. Gray RJ, Pockaj BA, Karstaedt PJ, Roarke MC. Radioactive seed localization of nonpalpable breast lesions is better than wire localization. *Am J Surg.* 2004;188(4):377–80.
  4. Medina-Franco H, Abarca-Perez L, Garcia-Alvarez MN, Ulloa-Gomez JL, Romero-Trejo C, Sepulveda-Mendez J. Radioguided occult lesion localization (ROLL) versus wire-guided lumpectomy for nonpalpable breast lesions: a randomized prospective evaluation. *J Surg Oncol.* 2008;97(2):108–11.
  5. Jacobs L. Positive margins: the challenge continues for breast surgeons. *Ann Surg Oncol.* 2008;15(5):1271–2.
  6. Coopey S, Smith BL, Hanson S, et al. The safety of multiple re-excisions after lumpectomy for breast cancer. *Ann Surg Oncol.* 2011;18(13):3797–801.
  7. Sharek D, Zuley ML, Zhang JY, Soran A, Ahrendt GM, Ganott MA. Radioactive seed localization versus wire localization for lumpectomies: a comparison of outcomes. *AJR Am J Roentgenol.* 2015;204(4):872–7.
  8. Cox CE, Furman B, Stowell N, et al. Radioactive seed localization breast biopsy and lumpectomy: can specimen radiographs be eliminated? *Ann Surg Oncol.* 2003;10(9):1039–47.
  9. Hughes JH, Mason MC, Gray RJ, et al. A multi-site validation trial of radioactive seed localization as an alternative to wire localization. *Breast J.* 2008;14(2):153–7.
  10. Jakub JW, Gray RJ, Degnim AC, Boughey JC, Gardner M, Cox CE. Current status of radioactive seed for localization of nonpalpable breast lesions. *Am J Surg.* 2010;199(4):522–8.
  11. McGhan LJ, McKeever SC, Pockaj BA, et al. Radioactive seed localization for nonpalpable breast lesions: review of 1000 consecutive procedures at a single institution. *Ann Surg Oncol.* 2011;18(11):3096–101.
  12. Alderliesten T, Loo CE, Pengel KE, Rutgers EJ, Gilhuijs KG, Vrancken Peeters MJ. Radioactive seed localization of breast lesions: an adequate localization method without seed migration. *Breast J.* 2011;17(6):594–601.
  13. Pan H, Wu N, Ding H, et al. Intraoperative ultrasound guidance is associated with clear lumpectomy margins for breast cancer: a systematic review and meta-analysis. *PLoS One.* 2013;8(9):e74028.
  14. Ahmed M, Douek M. Intraoperative ultrasound versus wire-guided localization in the surgical management of nonpalpable breast cancers: systematic review and meta-analysis. *Breast Cancer Res Treat.* 2013;140(3):435–46.
  15. Rahusen FD, Bremers AJ, Fabry HF, van Amerongen AH, Boom RP, Meijer S. Ultrasound-guided lumpectomy of nonpalpable breast cancer versus wire-guided resection: a randomized clinical trial. *Ann Surg Oncol.* 2002;9(10):994–8.
  16. Klein RL, Mook JA, Euhus DM, et al. Evaluation of a hydrogel-based breast biopsy marker (HydroMARK[R]) as an alternative to wire and radioactive seed localization for nonpalpable breast lesions. *J Surg Oncol.* 2012;105(6):591–4.
  17. Blumencranz PW, Ellis D, Barlowe K. Use of hydrogel breast biopsy tissue markers reduces the need for wire localization. *Ann Surg Oncol.* 2014;21(10):3273–7.
  18. Yu CC, Chiang KC, Kuo WL, Shen SC, Lo YF, Chen SC. Low reexcision rate for positive margins in patients treated with ultrasound-guided breast-conserving surgery. *Breast.* 2013;22(5):698–702.
  19. Ramos M, Diez JC, Ramos T, Ruano R, Sancho M, Gonzalez-Orus JM. Intraoperative ultrasound in conservative surgery for nonpalpable breast cancer after neoadjuvant chemotherapy. *Int J Surg.* 2014;12(6):572–7.
  20. Kaufman CS, Jacobson L, Bachman B, Kaufman LB. Intraoperative ultrasonography guidance is accurate and efficient according to results in 100 breast cancer patients. *Am J Surg.* 2003;186(4):378–82.
  21. Eggemann H, Ignatov T, Costa SD, Ignatov A. Accuracy of ultrasound-guided breast-conserving surgery in the determination of adequate surgical margins. *Breast Cancer Res Treat.* 2014;145(1):129–36.
  22. Murphy JO, Moo TA, King TA, et al. Radioactive seed localization compared to wire localization in breast-conserving surgery: initial 6-month experience. *Ann Surg Oncol.* 2013;20(13):4121–7.
  23. Lovrics PJ, Cornacchi SD, Vora R, Goldsmith CH, Kahn moui K. Systematic review of radioguided surgery for nonpalpable breast cancer. *Eur J Surg Oncol.* 2011;37(5):388–97.
  24. Lovrics PJ, Goldsmith CH, Hodgson N, et al. A multicentered, randomized, controlled trial comparing radioguided seed localization to standard wire localization for nonpalpable, invasive, and in situ breast carcinomas. *Ann Surg Oncol.* 2011;18(12):3407–14.