



# Less Toxicity. More Patients. Now *That's* SAVI.

## SAVI® CLINICAL CASE REVIEW

**Patient:** 47-year-old female  
**Diagnosis:** Invasive Ductal Carcinoma, T1, Stage 1  
**Rx:** 34Gy B.I.D. x 5 days delivered via single-entry, multi-catheter applicator  
**Challenge:** Maintaining safe dose limits to critical structures in patient with augmented breasts

The patient, a 47-year-old female with augmented breasts, was found to have a ductal carcinoma in the upper outer quadrant of the left breast. After discussion about surgical options, the patient opted for a breast conserving procedure to include Accelerated Partial Breast Irradiation (APBI).

A circumareolar incision was made and a generous core of tissue was taken around the guide wire to include the tumor. On frozen section, it appeared that margins were either close to or involved with the tumor. These were all re-excised, and upon further frozen section, no definitive in situ or invasive malignancy could be identified. Sentinel lymph node mapping revealed a radioactive sentinel lymph node which was excised from the surrounding axillary contents and found to be negative.

A SAVI 6-1Mini™ applicator was selected. Through a separate incision and using ultrasound guidance, a trocar was used to create a tract to the cavity and the SAVI applicator was placed via that tract.

For women with augmented breasts who are receiving breast irradiation, capsular contracture is a significant concern. For these women, breast brachytherapy represents the best opportunity to minimize radiation to the breast tissue/implant interface. Using the SAVI applicator, a treatment plan was developed which was able to sculpt the dose, limiting exposure the skin, chestwall, and implant *simultaneously*.

The initial treatment plan restricted dose to the skin to 100% of the prescription. After treatment fraction #7 (**Figure 1**) the patient began to exhibit early signs of erythema. The treatment plan was adjusted to reduce the dose to the skin to 75% of the prescription to alleviate these early symptoms. (**Figure 2**)

Following NSABP B-39 dosimetry criteria guidelines, the treatment plan yielded the following data:

Treatment Fractions	PTV	90%	V150	V200	Max Skin Dose	Max Chest Wall Dose
1-7	41.8cc	98.5%	18.6cc	10.0cc	340.9 cGy	164.6 cGy
8-10	32.8cc	91.6%	14.6cc	8.3cc	247 cGy	173 cGy

34 Gy was delivered B.I.D. for 5 days. Dressings were changed at each fraction. At one year follow up patient exhibits excellent cosmetic results. (**Figure 3**)

**Conclusion: The multiple catheters of the SAVI applicator allow for treatment planning flexibility that limits radiation dose to multiple critical structures as well as the ability to adjust that plan throughout the treatment regimen should symptoms present themselves.**

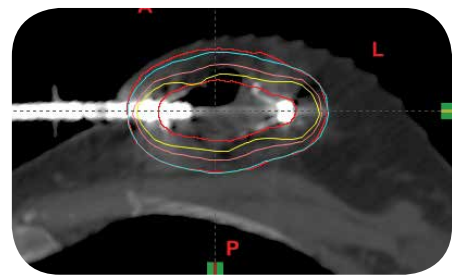


Figure 1

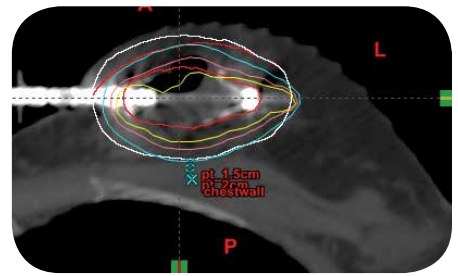


Figure 2

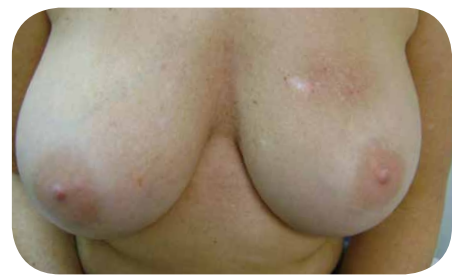

Figure 3

Case and photos provided by  
 Kerri L. Perry M.D., F.A.C.S., Denton, Texas



and

Zainab Ilahi M.D., Lewisville, Texas





[www.ciannamedical.com](http://www.ciannamedical.com)

Cianna Medical, Inc.  
6 Journey, Suite 125  
Aliso Viejo, California 92656  
866.920.9444  
949.360.0059  
Fax 949.297.4527

Customer Care:  
[info@ciannamedical.com](mailto:info@ciannamedical.com)

©2014 Cianna Medical, Inc. All rights reserved. These products covered by U.S. Patents 8,398,534, 7,662,082, 7,497,820, 7,497,819, 7,862,498, 7,862,496, 7,736,292, 7,601,113. Other patents pending. BEST Forum is a trademark of Cianna Medical, Inc. SAVI, SAVI Sisters and Cianna Medical are registered trademarks of Cianna Medical, Inc.