



## Early Clinical Experience with the SAVI™ Breast Brachytherapy Device

UNIVERSITY OF CALIFORNIA, SAN DIEGO



### Partial Breast Irradiation

Today, many women with early stage breast cancer are successfully treated with lumpectomy followed by a six-week course of daily external beam radiation to the whole breast. Despite the proven success of this approach, six weeks of treatment is a significant hardship for patients and may prevent many women from pursuing breast conservation therapy.<sup>1</sup> In addition, most local breast cancer recurrences occur in or near the tumor bed<sup>2</sup> and, in fact, the major benefit of external beam radiation is to reduce the risk of recurrence around the tumor bed.

As a result, more women are seeking an alternative treatment—accelerated partial breast irradiation (PBI) via high dose rate brachytherapy. High dose rate brachytherapy, which involves treating the area around a lumpectomy with a localized dose of radiation over a period of five days, minimizes radiation exposure to normal tissue and reduces logistical barriers for patients. Early reports on PBI are promising, and a definitive study comparing it with whole breast radiation is being conducted by the National Surgical Adjuvant Breast and Bowel Project (NSABP) and the Radiation Therapy Oncology Group (RTOG).

As part of its commitment to providing up-to-date treatment options for breast cancer, researchers at the Rebecca and John Moores UCSD Cancer Center at the University of California, San Diego, recently began using the SAVI applicator (Cianna Medical, Aliso Viejo, CA), a new single-entry, multi-catheter breast brachytherapy device. The center, a National Cancer Institute-designated Comprehensive Cancer Center, is one of the first medical facilities in the nation to offer the SAVI as part of breast conservation therapy.

Early results from UCSD demonstrate that the SAVI allows radiation to be delivered with precision to the area around the tumor bed, providing multiple benefits for patients, breast surgeons, and radiation

oncologists. These findings, based on experience with the first 13 patients, were presented by Dan Scanderbeg, Ph.D., at the 2007 annual meeting of the Radiological Society of North America (RSNA). Catheryn Yashar, M.D., assistant professor and chief of breast and gynecological services in the UCSD Department of Radiation Oncology, headed the research, along with Scanderbeg and Roger Rice, Ph.D.

### Treatment Modalities

At UCSD, partial breast irradiation is administered by four modalities, each with their advantages and limitations. In external beam irradiation, 4–5 beams of radiation are focused to pass through the skin and merge at the tumor site. External beam irradiation, which exposes more of the normal tissue to radiation, might not be an option for some patients, such as when the location of the lumpectomy cavity would require radiation to pass through the heart, lung, or shoulder.

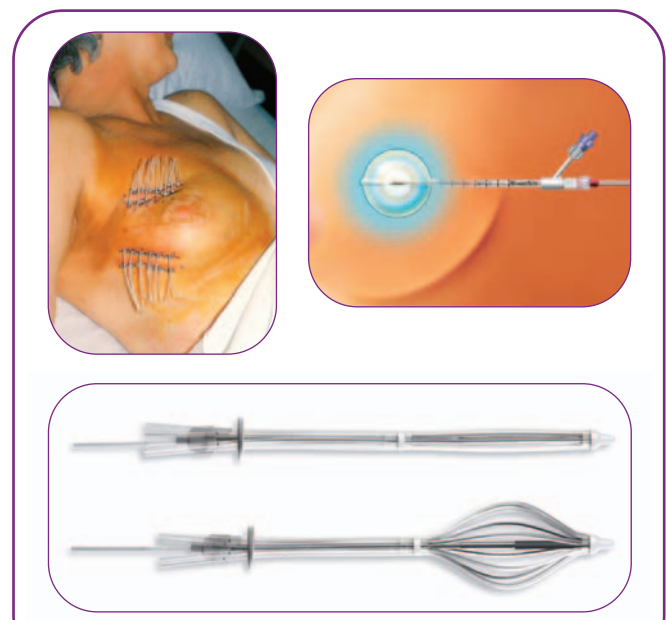


Figure 1. Top left: Interstitial breast brachytherapy; Top right: Single-catheter balloon device; Bottom: SAVI single-entry, multi-catheter breast brachytherapy device

Interstitial brachytherapy delivers radiation inside affected tissue through multiple catheters. (Figure 1) The catheters are individually passed through the skin and lumpectomy cavity, and the radiation source is inserted into the catheters for a short time, on the order of a few minutes, twice a day for five days. This modality is technically challenging and requires a high-level of clinical expertise.

In balloon brachytherapy (MammoSite, Cytac Corp., Marlborough, MA), a single-catheter balloon inserted through a single incision in a technically easy procedure delivers radiation. The saline-filled balloon approximates a sphere, and the single source of radiation is located in the center of that sphere. The radiation source is placed in the catheter for several minutes twice a day for five days. (Figure 1) This modality requires a spherical or egg-shaped lumpectomy cavity and may not be an option if the cavity and spherical distribution of radiation would fall too near the skin or ribs. Women with small breasts also might not be candidates for this modality.

*SAVI allows radiation to be delivered with precision to the area around the tumor bed, providing multiple benefits...*

The SAVI is the newest technological advance for PBI. This single-entry device has multiple peripheral hollow struts (6, 8, or 10 depending on the model used) and one central strut, into each of which is placed a radiation source. Through strategic selection of the dwell times of the radiation source placed into each of these independent struts, the desired treatment dose can be provided while minimizing radiation to nearby skin, chest wall, ribs, and muscle. The SAVI is in a collapsed configuration when introduced into the lumpectomy cavity, and after placement in the cavity, the device is expanded. (Figure 1)

### UCSD Experience with the SAVI

Clinicians at UCSD found that the SAVI combines the advantages of two other modalities for PBI. Like the other forms of brachytherapy, the SAVI provides good coverage of the tumor cavity and spares as much normal tissue as possible. The multiple,

peripheral struts of the SAVI each deliver an amount of radiation tailored for that exact location in the cavity, as do the multiple needles of interstitial brachytherapy.

In addition, like a balloon catheter, the SAVI is introduced via a single incision through the skin under local anesthesia.

UCSD's experience also showed that the SAVI avoids some of the major limitations of interstitial and balloon brachytherapy. Placement through a single incision is markedly easier than the introduction of the multiple needles required in interstitial brachytherapy. In addition, the multiple peripheral struts of the SAVI enabled radiation dose modulation in amounts customized for cavity characteristics, including proximity to the skin and chest wall, in contrast to the spherically symmetric distribution associated with balloon catheters, where radiation comes from a single point source.

### Use of the SAVI

Patients considering the SAVI discussed the option with their surgeons before lumpectomy. This was followed by an evaluation shortly after surgery, as the SAVI needs to be placed before scarring occurs around the cavity.

Within a few weeks after lumpectomy, the SAVI is placed into the tumor cavity. A local anesthetic is injected, and the appropriate-sized SAVI is inserted under ultrasound guidance through a single skin incision. (Figure 2)

After the SAVI is implanted, a ruler is used to measure the distance between the patient's skin and the hub of the device. To check placement and for planning purposes, a CT scan is made with fine (1.25 mm) slice thickness. In order to reduce motion artifact in the reconstructed images, a breath-hold technique is employed. Initial CT scout films also are taken.

Treatment planning consists of outlining the lumpectomy on the CT image and then drawing

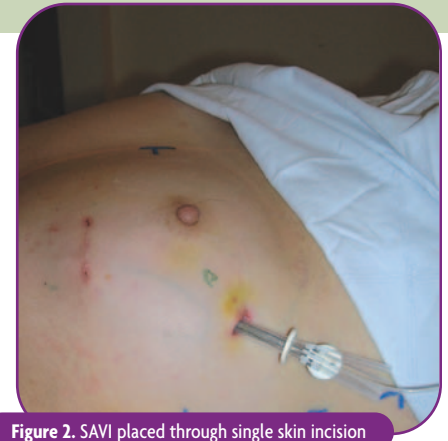

Figure 2. SAVI placed through single skin incision

an “expansion volume” 1 cm beyond the cavity. (Figure 3, left) The planning target volume (PTV) is defined as the difference between the expansion volume and the cavity. After any required modifications are made to the contour of the PTV, such as pulling it back from the skin in a region, optimization points are distributed on the periphery of the expansion volume. (Figure 3, center) The computer then optimizes dwell times for each radiation source position to give a 100% isodose distribution that corresponds to the PTV. (Figure 3, right)

Treatment is designed to satisfy three criteria:

- $V_{90\%}$  (volume of the PTV that receives 90% of the dose) must be  $> 90\%$
- $V_{150\text{cc}}$  (volume of the PTV that receives 150% of the dose) must be  $< 50\text{ cm}^3$
- $V_{200\text{cc}}$  (volume of the PTV that receives 200% of the dose) must be  $< 20\text{ cm}^3$

Table 1 shows the median and range of these volumes for the first 13 patients treated with the SAVI at UCSD.

The target volume then is irradiated twice a day for five days, with each session consisting of up to 10 minutes of radiation time. For each fraction, before the radiation source is placed in SAVI, the distance between the patient’s skin and the hub of the device is measured to check whether the device has moved in or out since original placement. Anterior-posterior and lateral CT scout films are taken to assess strut integrity. The scout films—not a full CT scan—also are used to check whether the device has rotated. Results in the initial patients

**Table 1. Dosimetry/Planning Results**

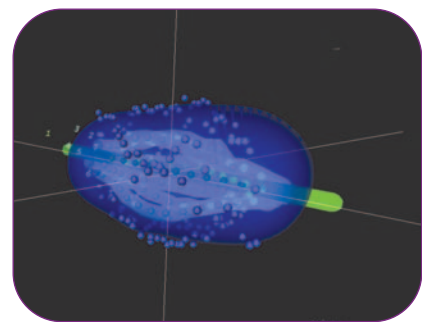
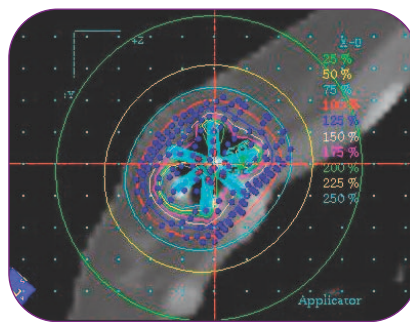
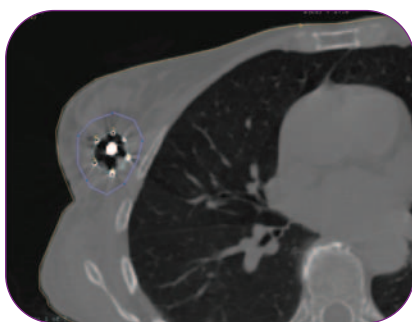
Median and Range (First 13 Patients)			
$V_{90}$	$V_{100}$	$V_{150}$	$V_{200}$
49.2 cc (91.7–21.0)	45.7 cc (85.9–18.8)	21.2 cc (40.6–8.2)	9.6 cc (18.7–3.7)
95.2% (99.6–82.0)	88.0% (96.8–69.6)	41.7% (52.8–31.4)	17.6% (26.6–10.3)

showed little translational or rotational displacement of the SAVI between fractions. Each fraction, preparation, irradiation, and dressing combine into about a 30-minute clinic visit for the patient.

When treatment is complete (after 10 fractions over five days), the SAVI is removed from the breast. Removal is nearly painless, and no anesthetic is used. Furthermore, early cosmetic results have been excellent.

## Conclusion

The armamentarium for breast cancer treatment expanded with the introduction of the the SAVI breast brachytherapy device. With additional treatment options, more women now can consider PBI. The choice should be based on the individual patient, characteristics of the tumor cavity, and the advantages and limitations of the treatment modalities. For those 13 patients at UCSD who selected PBI with the SAVI, the experience has been positive. The SAVI is technically easy to use and provides PBI that is customized to the location and shape of tumor cavities, even those lying close to the skin or other structures. ●



**Figure 3.** Left: Cavity defined as light green rule around tumor cavity; expansion volume defined as purple rule 1 cm beyond the cavity; Center: Optimization points (large blue dots) placed on the surface of the planning target volume (PTV) and red 100% isodose line conforming very well to PTV; Right: Computer-optimized dwell times for each strut in order to give a 100% isodose distribution as represented by the blue cloud rendered in the 3-D reconstruction

## SAVI Benefits to Patients

- Use of the SAVI to irradiate the tumor cavity after lumpectomy provides good coverage while minimizing radiation exposure to normal tissue.
- The technical ease of the SAVI compared with interstitial brachytherapy should enable the SAVI to be used by more clinicians and thus to be more widely available to patients.
- The SAVI is particularly advantageous for women with small breasts and where the tumor bed is close to the skin or chest wall.
- CT scout films showed little translational or rotational displacement of the SAVI applicator between fractions.
- Use of scout films instead of CTs to check position and integrity of the device before each session reduces patients' exposure to radiation. Less exposure to ionizing radiation could have long-term health benefits, especially for younger, otherwise healthy women.
- Treatment is one five-day course of two fractions per day, compared with five days a week for six weeks with external beam radiation. This shorter treatment course is logistically simpler and less burdensome for patients to the point that more women may complete a course of radiation.
- Removal of the SAVI applicator is nearly painless and does not require anesthetic.
- The SAVI thus far has shown excellent cosmetic results.

## References

1. Arthur DW, Vicini FA, Kuske RR, Wazer DE, Nag S. Accelerated partial breast irradiation: an updated report from the American Brachytherapy Society. *Brachytherapy*. 2002;1:184–190.
2. King TA, Bolton JS, Kuske RR, Fuhrman GM, Scroggins TG, Jiang XZ. Long-term results of wide-field brachytherapy as the sole method of radiation therapy after segmental mastectomy for T<sub>is,1,2</sub> breast cancer. *The American Journal of Surgery*. 2000;180:299–304.



6 Journey, Suite 125 • Aliso Viejo, California 92656  
Tel: 866.920.9444 or 949.360.0059 • Fax: 949.297.4527  
info@ciannamedical.com • www.ciannamedical.com